



ACOG COMMITTEE OPINION

Number 734 • May 2018

(Replaces Committee Opinion Number 440, August 2009)

Committee on Gynecologic Practice

This Committee Opinion was developed by the American College of Obstetricians and Gynecologists' Committee on Gynecologic Practice in collaboration with committee member Catherine Cansino, MD, MPH.

The Role of Transvaginal Ultrasonography in Evaluating the Endometrium of Women With Postmenopausal Bleeding

ABSTRACT: Cancer of the endometrium is the most common type of gynecologic cancer in the United States. Vaginal bleeding is the presenting sign in more than 90% of postmenopausal women with endometrial carcinoma. Clinical risk factors for endometrial cancer, including but not limited to age, obesity, use of unopposed estrogen, specific medical comorbidities (eg, polycystic ovary syndrome, type 2 diabetes mellitus, atypical glandular cells on screening cervical cytology), and family history of gynecologic malignancy also should be considered when evaluating postmenopausal bleeding. The clinical approach to postmenopausal bleeding requires prompt and efficient evaluation to exclude or diagnose endometrial carcinoma and endometrial intraepithelial neoplasia. Transvaginal ultrasonography usually is sufficient for an initial evaluation of postmenopausal bleeding if the ultrasound images reveal a thin endometrial echo (less than or equal to 4 mm), given that an endometrial thickness of 4 mm or less has a greater than 99% negative predictive value for endometrial cancer. Transvaginal ultrasonography is a reasonable alternative to endometrial sampling as a first approach in evaluating a postmenopausal woman with an initial episode of bleeding. If blind sampling does not reveal endometrial hyperplasia or malignancy, further testing, such as hysteroscopy with dilation and curettage, is warranted in the evaluation of women with persistent or recurrent bleeding. An endometrial measurement greater than 4 mm that is incidentally discovered in a postmenopausal patient without bleeding need not routinely trigger evaluation, although an individualized assessment based on patient characteristics and risk factors is appropriate. Transvaginal ultrasonography is not an appropriate screening tool for endometrial cancer in postmenopausal women without bleeding.

Recommendations and Conclusions

The American College of Obstetricians and Gynecologists makes the following recommendations and conclusions:

- The clinical approach to postmenopausal bleeding requires prompt and efficient evaluation to exclude or diagnose endometrial carcinoma and endometrial intraepithelial neoplasia.
- Transvaginal ultrasonography is appropriate for an initial evaluation of postmenopausal bleeding if the ultrasound images reveal a thin endometrial echo (less than or equal to 4 mm), given that an endometrial thickness of 4 mm or less has a greater than 99% negative predictive value for endometrial cancer.
- Transvaginal ultrasonography is a reasonable alternative to endometrial sampling as a first approach in evaluating a postmenopausal woman with an initial episode of bleeding.
- Transvaginal ultrasonography can be useful in the triage of women in whom office endometrial sampling was performed but tissue was insufficient for diagnosis.
- Failure to adequately identify a thin, distinct endometrial echo in a postmenopausal woman with bleeding should trigger sonohysterography, office hysteroscopy, or endometrial sampling.
- If blind sampling does not reveal endometrial hyperplasia or malignancy, further testing, such as

hysteroscopy with dilation and curettage, is warranted in the evaluation of women with persistent or recurrent bleeding.

- An axial uterus, obesity, coexisting myomas, adenomyosis, or previous uterine surgery can contribute to difficulty in obtaining reliable transvaginal ultrasound assessment of endometrial thickness and texture.
- Because rare cases of endometrial carcinoma (particularly type II) can present with an endometrial thickness of less than 3 mm, persistent or recurrent uterine bleeding should prompt a histologic evaluation of the endometrium regardless of endometrial thickness.
- An endometrial measurement greater than 4 mm that is incidentally discovered in a postmenopausal patient without bleeding need not routinely trigger evaluation, although an individualized assessment based on patient characteristics and risk factors is appropriate.

Cancer of the endometrium is the most common type of gynecologic cancer in the United States. In 2017, an estimated 61,380 new cases of uterine cancer were diagnosed and an estimated 10,920 deaths occurred (1). Most cases of uterine cancer (92%) occur in the endometrium and are referred to as endometrial cancer. Vaginal bleeding is the presenting sign in more than 90% of postmenopausal women with endometrial carcinoma (2). Postmenopausal

vaginal bleeding usually is caused by atrophic changes of the vagina or endometrium. Depending on age and risk factors, 1–14% of women with postmenopausal bleeding will have endometrial cancer (3–6). The clinical approach to postmenopausal bleeding requires prompt and efficient evaluation to exclude or diagnose endometrial carcinoma and endometrial intraepithelial neoplasia. This Committee Opinion describes the use of transvaginal ultrasonography for the evaluation of women with postmenopausal bleeding as well as the approach to the incidental finding of a thickened endometrial echo in asymptomatic postmenopausal women.

Transvaginal Ultrasonography

Endometrial thickness is measured as the maximum anterior–posterior thickness of the endometrial echo on a long-axis transvaginal view of the uterus. The earliest reports comparing transvaginal ultrasonography with endometrial sampling consistently found that an endometrial thickness of 4–5 mm or less in women with postmenopausal bleeding reliably excluded endometrial cancer (7–9). Since that time, a number of confirmatory multicenter trials have been completed (see Table 1). Transvaginal ultrasonography is appropriate for an initial evaluation of postmenopausal bleeding if the ultrasound images reveal a thin endometrial echo (less than or equal to 4 mm), given that an endometrial thickness of 4 mm or less has a greater than 99% negative predictive value for endometrial cancer.

Table 1. Endometrial Thickness and Cancer Findings in Postmenopausal Women With Bleeding [p.4](#)

Reference	Endometrial Thickness*	Number of Women With Noted Endometrial Thickness/ Total Sample Size	Number of Cases of Cancer	Negative Predictive Value [†]
Karlsson 1995 [‡]	≤4 mm	518/1,138	0	100%
Ferrazzi 1996 [§]	≤4 mm	336/930	2	99.4%
	≤5 mm	456/930	4	99.1%
Gull 2003	≤4 mm	178/339	0	100%
Wong 2016 [¶]	≤3 mm	1,915/4,383	5	99.7%
	≤4 mm	2,825/4,383	10	99.6%
	≤5 mm	3,131/4,383	11	99.6%

*Determined by transvaginal ultrasonography.

[†]Negative predictive value: The chance that a negative test result is a true negative.

[‡]Karlsson B, Granberg S, Wikland M, Ylostalo P, Torvid K, Marsal K, et al. Transvaginal ultrasonography of the endometrium in women with postmenopausal bleeding—a Nordic multicenter study. *Am J Obstet Gynecol* 1995;172:1488–94.

[§]Ferrazzi E, Torri V, Trio D, Zannoni E, Filiberto S, Dordoni D. Sonographic endometrial thickness: a useful test to predict atrophy in patients with postmenopausal bleeding. An Italian multicenter study. *Ultrasound Obstet Gynecol* 1996;7:315–21.

^{||}Gull B, Karlsson B, Milsom I, Granberg S. Can ultrasound replace dilation and curettage? A longitudinal evaluation of postmenopausal bleeding and transvaginal sonographic measurement of the endometrium as predictors of endometrial cancer. *Am J Obstet Gynecol* 2003;188:401–8.

[¶]Wong AS, Lao TT, Cheung CW, Yeung SW, Fan HL, Ng PS, et al. Reappraisal of endometrial thickness for the detection of endometrial cancer in postmenopausal bleeding: a retrospective cohort study. *BJOG* 2016;123:439–46.

Ultrasonography to measure endometrial echo should be offered as an initial evaluation only to women with postmenopausal bleeding for whom no further evaluation would be needed if a thin echo is found. Persistent or recurrent bleeding should trigger additional evaluation. Transvaginal ultrasonography is a reasonable alternative to endometrial sampling as a first approach in evaluating a postmenopausal woman with an initial episode of bleeding. Ultrasonography should be used only for patients whose prior probability of cancer and hyperplasia is low enough that no additional testing would be required after a normal ultrasonography. Endometrial sampling also is a reasonable first approach for women with postmenopausal bleeding (10). This initial evaluation does not require performance of both tests.

Clinical risk factors for endometrial cancer, including but not limited to age, obesity, use of unopposed estrogen, specific medical comorbidities (eg, polycystic ovary syndrome, type 2 diabetes mellitus, atypical glandular cells on screening cervical cytology), and family history of gynecologic malignancy also should be considered when evaluating postmenopausal bleeding. A retrospective cohort study of 4,383 women conducted in Hong Kong assessed endometrial cancer detection rates based on different cut-off levels and concluded that the predetermined threshold for further evaluation should be based on available resources, comorbidities, and acceptable detection rates (11). Endometrial sampling should be the first-line test for women with postmenopausal bleeding at higher risk (based on clinical risk factors or clinical presentation) of endometrial cancer and endometrial intraepithelial neoplasia. Table 2 demonstrates the number of cases of endometrial cancer missed by transvaginal ultrasonography based on different thresholds.

Using a 4 mm endometrial echo as a cut-off value, transvaginal ultrasonography has an extremely high negative predictive value (greater than 99%). However, a thickened endometrial echo is not diagnostic of any particular pathology. Even with an extremely high probability that a woman with a negative screening test result truly does not have the condition, a thin endometrial echo does not exclude all possibilities of disease. Furthermore, a thin endometrial echo does not reliably exclude type II endometrial cancer (uterine papillary serous, mucinous, clear cell) (12). Repeated episodes of postmenopausal bleeding and ongoing postmenopausal bleeding require histologic evaluation even in women with an apparent thin endometrial echo (10). Given its ease of performance, outpatient endometrial sampling with disposable devices is the primary method of choice for histologic evaluation. If blind sampling does not reveal endometrial hyperplasia or malignancy, further testing, such as hysteroscopy with dilation and curettage, is warranted in the evaluation of women with persistent or recurrent bleeding (10).

Limitations of Transvaginal Ultrasonography

It is not possible to complete a meaningful transvaginal ultrasound examination with a reliable measurement of endometrial thickness in all women (13–14). The thickest part of the endometrium should be measured perpendicular to its longitudinal plane in the anteroposterior diameter, representing the distance between the echogenic borders (Fig. 1) (15). An axial uterus, obesity, coexisting myomas, adenomyosis, or previous uterine surgery can contribute to difficulty in obtaining reliable transvaginal ultrasound assessment of endometrial thickness and texture. Failure to adequately identify a thin, distinct

Table 2. Composite Data on Missed Diagnoses of Endometrial Cancer Based on Different Thresholds of Endometrial Thickness

Threshold of Endometrial Thickness on Transvaginal Ultrasound	Number of Missed Diagnoses of Endometrial Cancer	Equivalent Fraction of Missed Diagnoses in Simplest Form
≤3 mm	5/1,915 cases of cancer	1 in 383
≤4 mm	12/4,073 cases of cancer	1 in 339
≤5 mm	15/3,587 cases of cancer	1 in 239

Data from Karlsson B, Granberg S, Wikland M, Ylostalo P, Torvid K, Marsal K, et al. Transvaginal ultrasonography of the endometrium in women with postmenopausal bleeding—a Nordic multicenter study. *Am J Obstet Gynecol* 1995;172:1488–94; Ferrazzi E, Torri V, Trio D, Zannoni E, Filiberto S, Dordoni D. Sonographic endometrial thickness: a useful test to predict atrophy in patients with postmenopausal bleeding. An Italian multicenter study. *Ultrasound Obstet Gynecol* 1996;7:315–21; Gull B, Karlsson B, Milsom I, Granberg S. Can ultrasound replace dilation and curettage? A longitudinal evaluation of postmenopausal bleeding and transvaginal sonographic measurement of the endometrium as predictors of endometrial cancer. *Am J Obstet Gynecol* 2003;188:401–8; and Wong AS, Lao TT, Cheung CW, Yeung SW, Fan HL, Ng PS, et al. Reappraisal of endometrial thickness for the detection of endometrial cancer in postmenopausal bleeding: a retrospective cohort study. *BJOG* 2016;123:439–46.

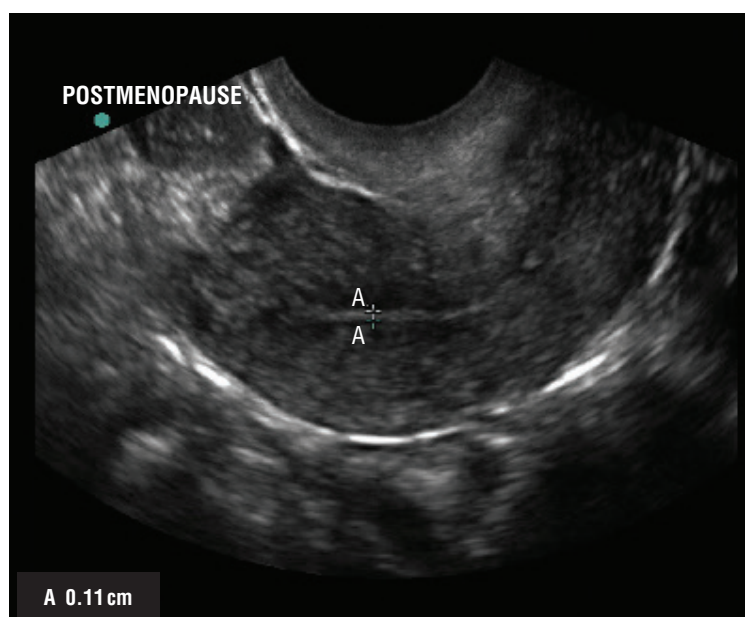


Figure 1. Measurement of endometrial thickness. The endometrial thickness measured at its thickest portion as the distance between the echogenic borders (calipers) perpendicular to the midline longitudinal plane of the uterus. ↩

endometrial echo in a postmenopausal woman with bleeding should trigger sonohysterography, office hysteroscopy, or endometrial sampling (10). In addition, endometrial fluid, when present, should not be included in measuring endometrial thickness. If an abnormal endometrium is identified, endometrial sampling is warranted.

Biopsy Findings of Tissue Insufficient for Diagnosis

Endometrial tissue sampling resulting in findings insufficient for diagnosis is common. In a study of 97 consecutive women with postmenopausal bleeding evaluated by transvaginal ultrasonography and endometrial biopsy, a pipelle biopsy was able to be performed in only 82% of the women (n=45) with an endometrial thickness of less than 5 mm (16). Of these women, a sample adequate for diagnosis was obtained in only 27%. There was no correlation between sample adequacy and parity or cavity length. In a meta-analysis of studies on women with postmenopausal bleeding, the range of sampling failure (eg, inadequate sample or inability to perform the biopsy) with biopsy was 0–54% (17). The associated sample size-weighted failure rate specifically with pipelle biopsy was 10.4% (17).

Transvaginal ultrasonography can be useful in the triage of women in whom office endometrial sampling was performed but tissue was insufficient for diagnosis (18). In one study, 29.8% of women evaluated for abnormal uterine bleeding had an “insufficient endometrial sample” (none of whom had endometrial hyperplasia or

cancer after the 2-year follow-up). No further evaluation is necessary after an insufficient endometrial biopsy if subsequent transvaginal ultrasonography demonstrates a thin echo in a woman with postmenopausal bleeding in whom bleeding has ceased (Table 1). Because rare cases of endometrial carcinoma (particularly type II) can present with an endometrial thickness of less than 3 mm, persistent or recurrent uterine bleeding should prompt a histologic evaluation of the endometrium regardless of endometrial thickness (10).

Postmenopausal Women Without Bleeding

The utility of transvaginal ultrasonography to exclude pathology in postmenopausal women with bleeding should not be extrapolated to asymptomatic postmenopausal women without bleeding. In 1,750 postmenopausal women without bleeding who were screened for a selective estrogen receptor modulator study, an endometrial thickness of 6 mm or less had a negative predictive value of 99.94% for excluding malignancy (only one case of cancer in 1,750 women) and a 99.77% negative predictive value for complex hyperplasia (only four cases in 1,750 women) (19). Among 42 women with endometrial thickness of greater than 6 mm, there was one case of adenocarcinoma and no cases of hyperplasia (positive predictive value of 2.4%). In another study, 82 asymptomatic postmenopausal women had an incidental ultrasonographic finding of a thick endometrial echo suspected to be a polyp (20). All women underwent

operative hysteroscopy. Of these women, a benign polyp was found in 68, submucosal myoma in 7, atrophic endometrium in 6, and proliferative endometrium in 1. One polyp contained simple hyperplasia. There were no cases of endometrial carcinoma or complex hyperplasia. The total complication rate was 3.6% (two perforations, one difficult intubation). An asymptomatic population of postmenopausal Danish women who were randomly selected from a civil registry revealed that 13% had a nonbleeding polyp detected by sonohysterography (21).

A retrospective multicenter trial in which 1,152 polyps were removed from asymptomatic postmenopausal women diagnosed by sonohysterography reported one case of stage 1 grade 1 carcinoma (22). The incidence of any cancer in this trial of asymptomatic women was 1 in 288. A retrospective study of 190 postmenopausal women with symptomatic endometrial carcinoma and 123 asymptomatic women with suspicious endometrium detected by transvaginal ultrasonography found no prognostic advantage in terms of 5-year survival between women with cancer discovered incidentally and those treated within 8 weeks of their clinical presentation of postmenopausal bleeding (23).

An endometrial measurement greater than 4 mm that is incidentally discovered in a postmenopausal patient without bleeding need not routinely trigger evaluation, although an individualized assessment based on patient characteristics and risk factors is appropriate. Thus, transvaginal ultrasonography is not an appropriate screening tool for endometrial cancer in postmenopausal women without bleeding.

References

1. American Cancer Society. *Cancer facts and figures 2017*. Atlanta (GA): ACS; 2017. ↩
2. Goldstein RB, Bree RL, Benson CB, Benacerraf BR, Bloss JD, Carlos R, et al. Evaluation of the woman with postmenopausal bleeding: Society of Radiologists in Ultrasound-Sponsored Consensus Conference statement. *J Ultrasound Med* 2001;20:1025–36. ↩
3. Smith-Bindman R, Kerlikowske K, Feldstein VA, Subak L, Scheidler J, Segal M, et al. Endovaginal ultrasound to exclude endometrial cancer and other endometrial abnormalities. *JAMA* 1998;280:1510–7. ↩
4. Tabor A, Watt HC, Wald NJ. Endometrial thickness as a test for endometrial cancer in women with postmenopausal vaginal bleeding. *Obstet Gynecol* 2002;99:663–70. ↩
5. Gupta JK, Chien PF, Voit D, Clark TJ, Khan KS. Ultrasonographic endometrial thickness for diagnosing endometrial pathology in women with postmenopausal bleeding: a meta-analysis. *Acta Obstet Gynecol Scand* 2002;81:799–816. ↩
6. Smith-Bindman R, Weiss E, Feldstein V. How thick is too thick? When endometrial thickness should prompt biopsy in postmenopausal women without vaginal bleeding. *Ultrasound Obstet Gynecol* 2004;24:558–65. ↩
7. Goldstein SR, Nachtigall M, Snyder JR, Nachtigall L. Endometrial assessment by vaginal ultrasonography before endometrial sampling in patients with postmenopausal bleeding. *Am J Obstet Gynecol* 1990;163:119–23. ↩
8. Varner RE, Sparks JM, Cameron CD, Roberts LL, Soong SJ. Transvaginal sonography of the endometrium in postmenopausal women. *Obstet Gynecol* 1991;78:195–9. ↩
9. Granberg S, Wikland M, Karlsson B, Norstrom A, Friberg LG. Endometrial thickness as measured by endovaginal ultrasonography for identifying endometrial abnormality. *Am J Obstet Gynecol* 1991;164:47–52. ↩
10. Endometrial cancer. Practice Bulletin No. 149. American College of Obstetricians and Gynecologists. *Obstet Gynecol* 2015;125:1006–26. ↩
11. Wong AS, Lao TT, Cheung CW, Yeung SW, Fan HL, Ng PS, et al. Reappraisal of endometrial thickness for the detection of endometrial cancer in postmenopausal bleeding: a retrospective cohort study. *BJOG* 2016;123:439–46. ↩
12. Wang J, Wieslander C, Hansen G, Cass I, Vasilev S, Holschneider CH. Thin endometrial echo complex on ultrasound does not reliably exclude type 2 endometrial cancers. *Gynecol Oncol* 2006;101:120–5. ↩
13. Sit AS, Modugno F, Hill LM, Martin J, Weissfeld JL. Transvaginal ultrasound measurement of endometrial thickness as a biomarker for estrogen exposure. *Cancer Epidemiol Biomarkers Prev* 2004;13:1459–65. ↩
14. Ragupathy K, Cawley N, Ridout A, Iqbal P, Alloub M. Non-assessable endometrium in women with post-menopausal bleeding: to investigate or ignore. *Arch Gynecol Obstet* 2013;288:375–8. ↩
15. American College of Radiology. *ACR–ACOG–AIUM–SRU practice parameter for the performance of ultrasound of the female pelvis*. Reston (VA): ACR; 2014. ↩
16. Elsandabese D, Greenwood P. The performance of Pipelle endometrial sampling in a dedicated postmenopausal bleeding clinic. *J Obstet Gynaecol* 2005;25:32–4. ↩
17. Dijkhuizen FP, Mol BW, Brolmann HA, Heintz AP. The accuracy of endometrial sampling in the diagnosis of patients with endometrial carcinoma and hyperplasia: a meta-analysis. *Cancer* 2000;89:1765–72. ↩
18. Bakour SH, Khan KS, Gupta JK. Controlled analysis of factors associated with insufficient sample on outpatient endometrial biopsy. *BJOG* 2000;107:1312–4. ↩
19. Fleischer AC, Wheeler JE, Lindsay I, Hendrix SL, Grabill S, Kravitz B, et al. An assessment of the value of ultrasonographic screening for endometrial disease in postmenopausal women without symptoms. *Am J Obstet Gynecol* 2001;184:70–5. ↩
20. Lev-Sagie A, Hamani Y, Imbar T, Hurwitz A, Lavy Y. The significance of intrauterine lesions detected by ultrasound in asymptomatic postmenopausal patients. *BJOG* 2005;112:379–81. ↩
21. Dreisler E, Stampe Sorensen S, Ibsen PH, Lose G. Prevalence of endometrial polyps and abnormal uterine bleeding in a Danish population aged 20–74 years. *Ultrasound Obstet Gynecol* 2009;33:102–8. ↩
22. Ferrazzi E, Zupi E, Leone FP, Savelli L, Omodei U, Moscarini M, et al. How often are endometrial polyps malignant in asymptomatic postmenopausal women? A multicenter study. *Am J Obstet Gynecol* 2009;200:235.e1–6. ↩

23. Gerber B, Krause A, Muller H, Reimer T, Kulz T, Kundt G, et al. Ultrasonographic detection of asymptomatic endometrial cancer in postmenopausal patients offers no prognostic advantage over symptomatic disease discovered by uterine bleeding. *Eur J Cancer* 2001;37:64–71. ↩

Copyright May 2018 by the American College of Obstetricians and Gynecologists. All rights reserved. No part of this publication may be reproduced, stored in a retrieval system, posted on the Internet, or transmitted, in any form or by any means, electronic, mechanical, photocopying, recording, or otherwise, without prior written permission from the publisher.

Requests for authorization to make photocopies should be directed to Copyright Clearance Center, 222 Rosewood Drive, Danvers, MA 01923, (978) 750-8400.

**American College of Obstetricians and Gynecologists.
409 12th Street, SW, PO Box 96920, Washington, DC 20090-6920**

The role of transvaginal ultrasonography in evaluating the endometrium of women with postmenopausal bleeding. ACOG Committee Opinion No. 734. *American College of Obstetricians and Gynecologists*. *Obstet Gynecol* 2018;131:e124–9.

This information is designed as an educational resource to aid clinicians in providing obstetric and gynecologic care, and use of this information is voluntary. This information should not be considered as inclusive of all proper treatments or methods of care or as a statement of the standard of care. It is not intended to substitute for the independent professional judgment of the treating clinician. Variations in practice may be warranted when, in the reasonable judgment of the treating clinician, such course of action is indicated by the condition of the patient, limitations of available resources, or advances in knowledge or technology. The American College of Obstetricians and Gynecologists reviews its publications regularly; however, its publications may not reflect the most recent evidence. Any updates to this document can be found on www.acog.org or by calling the ACOG Resource Center.

While ACOG makes every effort to present accurate and reliable information, this publication is provided “as is” without any warranty of accuracy, reliability, or otherwise, either express or implied. ACOG does not guarantee, warrant, or endorse the products or services of any firm, organization, or person. Neither ACOG nor its officers, directors, members, employees, or agents will be liable for any loss, damage, or claim with respect to any liabilities, including direct, special, indirect, or consequential damages, incurred in connection with this publication or reliance on the information presented.

All ACOG Committee members and authors have submitted a conflict of interest disclosure statement related to this published product. Any potential conflicts have been considered and managed in accordance with ACOG’s Conflict of Interest Disclosure Policy. The ACOG policies can be found on acog.org. For products jointly developed with other organizations, conflict of interest disclosures by representatives of the other organizations are addressed by those organizations. The American College of Obstetricians and Gynecologists has neither solicited nor accepted any commercial involvement in the development of the content of this published product.